

Linfoma T Primário Bilateral da Supra-Renal: Um Caso Clínico

Primary Bilateral Adrenal T-Cell Lymphoma: A Case Report

Sara Castelo Branco (<https://orcid.org/0000-0003-0993-7660>)¹, João Rosinhas (<https://orcid.org/0000-0001-9644-691X>)¹, Artur Silva (<https://orcid.org/0000-0001-8540-7659>)², António Taveira Gomes (<https://orcid.org/A-4832-2014> // [0000-0002-4637-2374](https://orcid.org/0000-0002-4637-2374))³, Ana Espírito Santo (<https://orcid.org/0000-0002-4840-590X>)⁴, António Furtado (<https://orcid.org/0000-0001-7859-1259>)¹

Resumo

O linfoma primário da supra-renal é uma entidade extremamente rara que constitui menos de 1% dos linfomas extra-nodais. A maioria dos casos apresenta-se com massas bilaterais na supra-renal, com ou sem envolvimento extra-nodal. Uma das manifestações mais graves é a insuficiência supra-renal. O mecanismo etiológico não está completamente esclarecido, mas acredita-se que a auto-imunidade tenha um papel importante. Apresentamos o caso de um homem de 44 anos, internado no Departamento de Medicina Interna por dor torácica, sintomas constitucionais e febre. Uma tomografia computadorizada abdominal mostrou massas supra-renais bilaterais. Efetuou-se uma adrenalectomia esquerda e o exame histológico revelou tratar-se de um linfoma não-Hodgkin de células-T. Da revisão da literatura, foram descritos apenas 5 casos de linfoma T primário da supra-renal. Este caso clínico enfatiza a complexidade do diagnóstico diferencial perante massas bilaterais da supra-renal, alertando para a possibilidade de linfoma cuja precocidade diagnóstica tem impacto prognóstico. Uma revisão da literatura sobre esta entidade pouco frequente foi realizada.

Palavras-chave: Autoimunidade; Linfoma de Células T; Neoplasias das Glândulas Suprarrenais

Abstract

Primary adrenal lymphoma is an extremely rare entity which constitutes less than 1% of all extranodal lymphomas. Most cases are presented with bilateral adrenal masses with or without extra-adrenal involvement. Presentation may be with adrenal insufficiency which can be a life-threatening situation. The etiological mechanism is not completely understood but autoimmunity seems to have an important role. We report a case of a 44-year old man admitted to the Internal Medicine Department due to thoracic pain, constitutional symptoms and fever. An abdominal computed tomography scan revealed bilateral adrenal masses. A left surgical adrenalectomy was performed, and histological examination diagnosed a non-Hodgkin T-cell lymphoma. Only 5 cases of T-cell type PAL have been reported in literature. This case report emphasizes the complexity of differential diagnosis in the presence of bilateral adrenal masses, the possibility of lymphoma and the importance of early diagnosis in order to improve the clinical outcomes. A review of the literature of this unusual entity was carried out.

Keywords: Adrenal Gland Neoplasms; Autoimmunity; Lymphoma, T-Cell

Introduction

Primary adrenal lymphoma (PAL) is a rare entity accounting for less than 1% of non-Hodgkin lymphomas. It has a bilateral presentation in nearly 70% of cases. In these cases, the development of adrenal insufficiency is more frequent.^{1,2} The most common type of PAL is diffuse large B cell lymphoma, which comprises more than 70% of the cases.³⁻⁵ Chemotherapy is the first-line treatment option and the prognosis is usually poor.^{6,7}

We report a case of bilateral T-cell PAL. A review of the literature on the most relevant clinical aspects of the PAL was performed.

Case Report

A 44-year old male, current smoker of 25 pack-year and with chronic pulmonary obstructive disease, was admitted to our hospital with bilateral, posterior, inferior thoracic pain,

¹Serviço de Medicina Interna, Hospital Pedro Hispano, Matosinhos, Portugal

²Serviço de Anatomia Patológica, Hospital Pedro Hispano, Matosinhos, Portugal

³Serviço de Cirurgia Geral, Hospital Pedro Hispano, Matosinhos, Portugal

⁴Serviço de Hemato-Oncologia, Instituto Português de Oncologia do Porto, Porto, Portugal

<https://revista.spmi.pt> - DOI:10.24950/rspm/CC/210/18/3/2019

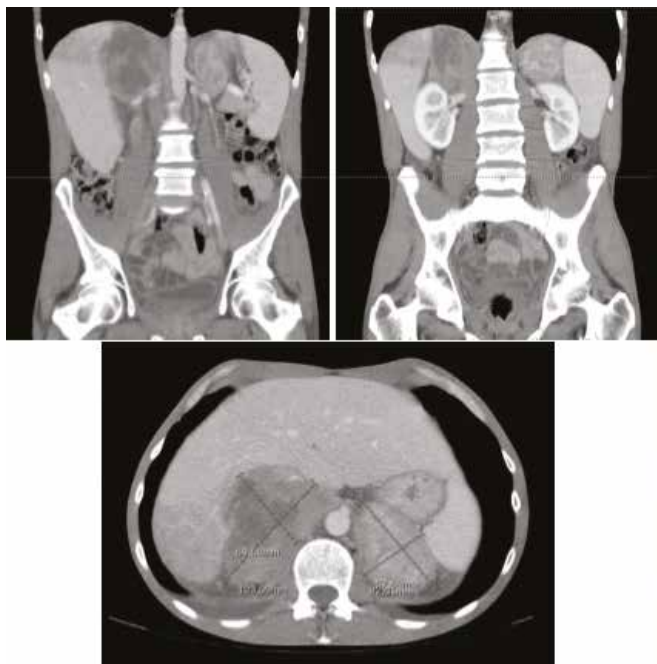


Figure 1: Abdominal CT-scan showing heterogeneous adrenal masses in both adrenal glands.

anorexia and asthenia persisting for 2 weeks and fever since the day before. In two months before admission he had been diagnosed with anterior unilateral uveitis and treated with topical corticosteroid. He reported unintentional loss of approximately 10% of his body weight during the last year.

On admission, his blood pressure was 85/65 mmHg, his heart rate was 98 beats per minute and his tympanic temperature was 38.2°C. He had tanned skin and there were no enlarged lymph nodes, hepatosplenomegaly or other positive physical examination findings. A full blood count and erythrocyte sedimentation rate were normal. The biochemical profile showed potassium 5.8 mEq/L (reference range 3.4-5.1 mEq/L), sodium 128 mEq/L (reference range 136-145 mEq/L), normal serum calcium and serum creatinine, C-reactive protein 23.8 mg/L (reference range < 5 mg/L), LDH 645 U/L (reference range 125-220 U/L) and ferritin 1361 ng/mL (reference range 21-274 ng/mL). The thoracic and abdominal computed tomography (CT) scan showed two heterogeneous masses, one on the right adrenal gland with 10 x 6 x 9 cm and other on the left adrenal gland with 8 x 4 x 4.5 cm (Fig. 1).

We started the diagnostic investigation based on the differential diagnosis aimed at bilateral adrenal masses, such as granulomatous disorders, non-functioning adenoma, pheochromocytoma, adrenocortical carcinoma or metastatic tumor.

Based on the clinical presentation (with anorexia, asthenia, weight loss, hypotension and tanned skin) and the ionic disturbances (hyponatremia and hyperkalemia), the possibility of adrenal insufficiency was considered. For this reason, the patient started intravenous dexamethasone 10 mg id.

Plasma fasting blood glucose, aldosterone to renin ratio,

serum cortisol, corticotropin (ACTH), urinary and plasma fractionated metanephrines and catecholamines and 24-hour free cortisol were normal.

During the rest of his hospitalization, he remained non-febrile and the biochemical profile showed no elevation of inflammatory markers.

The HIV 1 and 2 serology was negative, tuberculin skin test and interferon-gamma release assay excluded tuberculosis and angiotensin converting enzyme was normal.

Taking into account the recent unilateral uveitis, immunological studies were performed and ANA, anti-dsDNA, ANCA, complement, IgG, IgA and IgM were normal. Infection with Epstein-Barr virus (EBV), herpes simplex viruses (HSV) 1 and 2 and cytomegalovirus (CMV) was ruled out.

Two percutaneous needle core biopsies were performed but revealed inconclusive. Left adrenalectomy was performed. Culture of the adrenal masses was negative for *Mycobacterium tuberculosis* (cultural exam and polymerase chain reaction), other bacteria and fungi. Culture of blood from peripheral vein was also performed and was negative.

The histological examination revealed a non-Hodgkin T-cell lymphoma (Figs 2 and 3). There was no evidence of bone marrow involvement at that time. In light of the association between T-cell lymphoma and HTLV 1 infection, at this time infection by the virus was excluded.

Two weeks later the patient developed surgical wound dehiscence with purulent exudate, fever and shivering with renal dysfunction (pCr 2.8 mg/dL, pU 158 mg/dL) and oliguria. Electrolytes abnormalities reveal, hyperphosphatemia (Phosphorus 6.2 mg/dL, reference range 2.3-4.7 mg/dL) and hypocalcemia (Ionized calcium 1.02 mmol/L, reference range 1.15-1.35 mmol/L), elevated DHL (DHL 911 U/L reference range 125-220 U/L) with normal uric acid and urine sediment. He started therapy with piperacilin and tazobactam. Abdominal computed tomography (CT) scan was repeated which showed kidney, spleen, hepatic and inferior vena cava involvement by the lymphoma. Acute renal dysfunction was interpreted as a result of sepsis dysfunction, lymphoma progression and cellular lysis. The patient started renal replacement therapy.

After infection control, the patient started rasburicase and chemotherapy with cyclophosphamide 1200 mg, hydroxydoxorubicin 80 mg, vincristine 2 mg and prednisolone 100 mg (CHOP). After only one chemotherapy cycle, the patient developed nosocomial respiratory infection with shock and multiorgan failure. He was admitted in the intensive care unit. Despite appropriate treatment the patient deceased on the 30th day.

Discussion

PAL is a very rare type of extranodal lymphoma with only about 200 cases described in the literature.⁵ The male:female ratio is approximately 1.8:1 and the mean age at diagnosis is 62 years old.^{1,8}

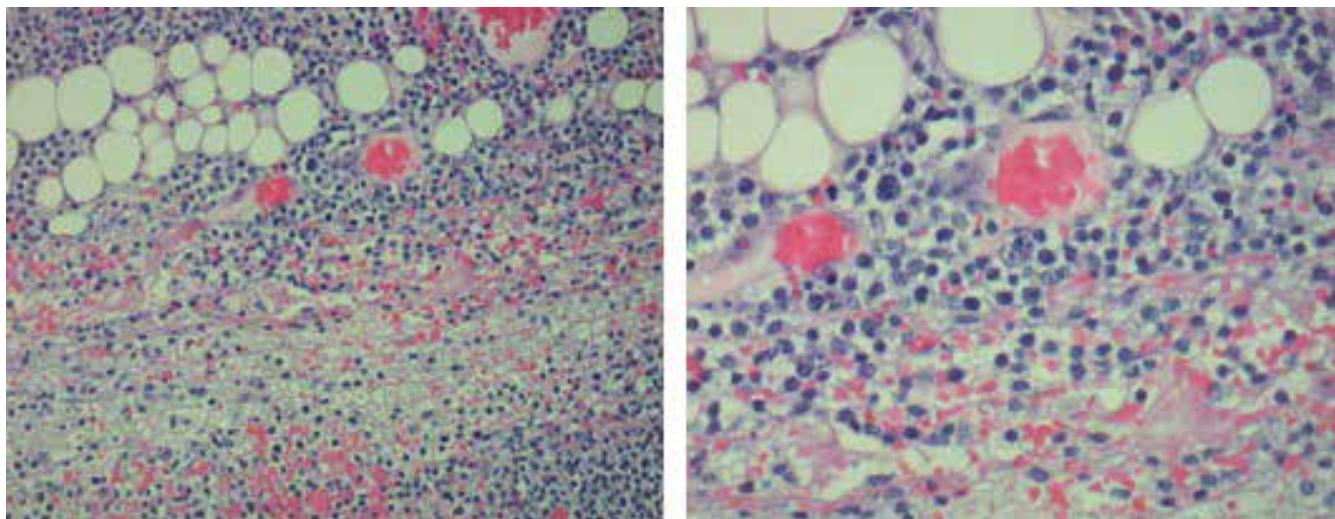


Figure 2: (H&E). Adrenal gland infiltrated by medium-sized atypical cells with large, vesicular nuclei, some of them horseshoe-shaped, with prominent nucleoli and scarce cytoplasm.

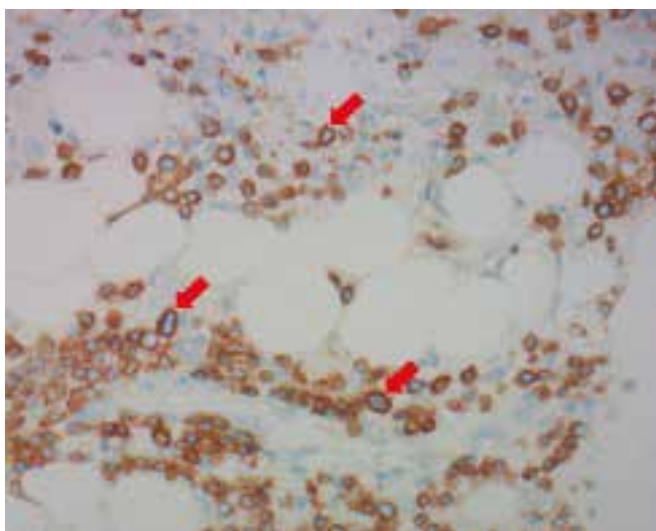


Figure 3: On the immunohistochemical exam there's immunoreaction of the atypical cells for CD3 antibody, a T-cell lymphoid marker (red arrows).

The exact pathogenesis is still unknown, although an association with auto-immune disease and immunodeficiency states has been described.^{9,10} Our patient had a recent diagnosis of unilateral uveitis suggesting an immune mechanism in the pathogenesis of the lymphoma. In the literature, uveitis prior to T-cell lymphomas has been described.¹¹

Clinical presentation are nonspecific symptoms and B-symptoms, pain and fatigue are the most frequent.^{1,4,5} Skin/mucosal hyperpigmentation, hepatosplenomegaly and lymphadenopathies were described by Rashidi in 27% of the cases. Less common symptoms are anorexia, nausea/vomiting, neurological symptoms and diarrhea.⁵ CT scan is the exam of choice for the diagnosis of adrenal glands masses. There are no pathognomonic CT scan features for

PAL. Usually it shows homogenous masses with predominantly low density and slight to moderate enhancement.^{5,12} The definitive diagnosis is made by anatomopathological examination. Secondary involvement of both adrenal glands has been reported in 12% of patients with non-Hodgkin's lymphoma but primary bilateral adrenal lymphoma is much rarer. Of those cases with primary involvement high-grade diffuse B cell lymphoma is the predominant histological subtype of PAL (approximately 78%); while T-cell has only been reported in 7% of the cases.³⁻⁶ The definitive diagnosis may be difficult when heterogeneous masses are present, especially when lesions are confined to the adrenal gland. After ruling out frequent causes of bilateral adrenal masses, such as granulomatous disorders, non-functioning adenoma, pheochromocytoma, adrenocortical carcinoma or metastatic tumor, we end up to histologically diagnose an extremely rare PAL.⁴ To the best of our knowledge, only 5 cases of T-cell type PAL have been reported in literature.¹³

The best therapeutic approach is not established. Treatment options include chemotherapy, surgery and surgery followed by chemotherapy. The role of radiation therapy and autologous peripheral blood stem cell is still unclear.⁵ Chemotherapy remains the cornerstone in the management of PAL. The classical regimen is CHOP, with or without rituximab. Response rates are low and have been achieved mainly in patients in early stages.^{2,7,8} Because of the life-threatening consequences of adrenal insufficiency, glucocorticoid replacement therapy might be necessary. Despite optimized treatment, prognosis is poor with median survival usually less than 1 year.^{12,14} Poor prognostic factors include advanced age, large tumor size, bilateral involvement, high LDH levels, involvement of other organs and initial presentation with adrenal insufficiency.^{5,12} Our patient presented with large bilateral masses and high LDH levels despite young age.

Conclusion

We report a case of an extremely rare form of T-cell PAL. The prognosis of bilateral PAL is poor, chemotherapy is the first line therapy and responses were described in early stages. This case report intends to emphasize the complexity of differential diagnosis in the presence of bilateral adrenal mass, the possibility of lymphoma and the importance of early diagnosis in order to improve the clinical outcomes. ■

Acknowledgements

We thank Dr. Ana Costa, Hospital Pedro Hispano, Matosinhos, who kindly supplied additional valuable data.

Responsabilidades Éticas

Conflitos de Interesse: Os autores declaram a inexistência de conflitos de interesse na realização do presente trabalho.

Fontes de Financiamento: Não existiram fontes externas de financiamento para a realização deste artigo.

Confidencialidade dos Dados: Os autores declaram ter seguido os protocolos da sua instituição acerca da publicação dos dados de doentes.

Consentimento: Consentimento do doente para publicação obtido. Proveniência e Revisão por Pares: Não comissionado; revisão externa por pares.

Ethical Disclosures

Conflicts of Interest: The authors have no conflicts of interest to declare.

Financing Support: This work has not received any contribution, grant or scholarship.

Confidentiality of Data: The authors declare that they have followed the protocols of their work center on the publication of data from patients.

Patient Consent: Consent for publication was obtained.

Provenance and Peer Review: Not commissioned; externally peer reviewed.

© Autor (es) (ou seu (s) empregador (es)) 2019. Reutilização permitida de acordo com CC BY-NC. Nenhuma reutilização comercial.

© Author(s) (or their employer(s)) 2019. Re-use permitted under CC BY-NC. No commercial re-use.

Correspondence/Correspondência:

Sara Castelo Branco – sara.castellobranco@gmail.com
Serviço de Medicina Interna, Hospital Pedro Hispano, Matosinhos, Portugal
Rua Dr. Eduardo Torres, 4464-513 Senhora da Hora

Received/Recebido: 13/09/2018

Accepted/Aceite: 08/11/2018

Publicado / Published: 20, de Setembro de 2019

REFERÊNCIAS

- Ozimek A, Diebold J, Linke R, Heyn J, Hallfeldt K, Mussak T. Bilateral primary adrenal non-Hodgkin's lymphoma and primary adrenocortical carcinoma review of the literature preoperative differentiation of adrenal tumors. *Endocr J*. 2008; 55: 625-38.
- Aziz SA, Laway BA, Rangreze I, Lone MI, Ahmad SN. Primary adrenal lymphoma: differential involvement with varying adrenal function. *Indian J Endocrinol Metab*. 2011; 15: 220-3. doi: 10.4103/2230-8210.83414.

- Libè R, Giavoli C, Barbetta L, Dall'Asta C, Passini E, Buffa R, et al. A primary adrenal non-Hodgkin's lymphoma presenting as an incidental adrenal mass. *Exp Clin Endocrinol Diabetes*. 2006; 114: 140-4. doi:10.1055/s-2005-865913.
- Mantzios G, Tsigotis P, Veliou F, Boutsikakis I, Petraki L, Kolovos J, et al. Primary adrenal lymphoma presenting as Addison's disease: case report and review of the literature. *Ann Hematol*. 2004; 83: 460-3. doi: 10.1007/s00277-003-0838-3.
- Rashidi A, Fisher SI. Primary adrenal lymphoma: a systematic review. *Ann Hematol*. 2013; 92: 1583-93. doi: 10.1007/s00277-013-1812-3.
- Horiguchi K, Hashimoto K, Hasizume M, Masuo T, Suto M, Okaio J. Primary bilateral adrenal diffuse large B-cell lymphoma demonstrating adrenal failure. *Intern Med*. 2010; 49: 2241-6. doi: 10.2169/internalmedicine.49.3941.
- Kim YR, Kim JS, Min YH, Hyunyon D, Shin HJ, Mun YC. Prognostic factors in primary diffuse large B-cell lymphoma of adrenal gland treated with rituximab-CHOP chemotherapy from the consortium for improving survival of lymphoma (CISL). *J Hematol Oncol*. 2012; 5: 49. doi:10.1186/1756-8722-5-49.
- Lim KH, Chiou TY, Lin CJ, Hsieh RK. Rituximab in the treatment of primary bilateral adrenal lymphoma with adrenal crisis. *Med Oncol*. 2008; 25:107-9. doi: 10.1007/s12032-007-0051-7.
- Dutta P, Bhansali A, Venkatesan R, Mittal RB, Kumar V. Primary adrenal lymphoma. *Endocrinologist*. 2005; 15:340-2.
- Reddy SB, Gnanasekaran B, Prabhudesai S. Origin of primary adrenal lymphoma and predisposing factors for primary adrenal insufficiency in primary adrenal lymphoma. *Indian J Endocrinol Metab*. 2011;15:350-1. doi: 10.4103/2230-8210.85604.
- Lai Y, Zhang M, Wang L, Yang A, Li J, Zhang X, et al. Uveitis and T cell lymphoma: a rare but notable relationship. *Med Oncol*. 2014; 31:992. doi: 10.1007/s12032-014-0992-6.
- Grigg AP, Connors JM. Primary adrenal lymphoma. *Clin Lymphoma*. 2003;4:154-60.
- Bommannan K, Sachdeva M, Sekar A, Kumar R, Dey P. Primary adrenal T-cell lymphoma in a young adult presented with pseudo-hypopyony: a case report and literature review. *Blood Res*. 2017;52:227-9. doi: 10.5045/br.2017.52.3.227.
- Rizzo C, Camilleri DJ, Betts A, Gatt A, Fava S. Primary bilateral non-Hodgkin's lymphoma of the adrenal gland presenting as incidental adrenal masses. *Case Rep Med*. 2015; 620381.